

## Profile of Giant Abdominal Masses: An Experience of 30 Cases and Review of Literature

Talib Hussain, Sanjay Sharma, Abhinav Mani, Sanjay Kumar Bhasin.

### Abstract

#### Background and aim

Giant abdominal mass has not been a common presentation in the era of advanced radiological diagnostic modalities especially in socio-educationally well developed societies. In developing nations like India, patients with Giant abdominal masses do present, requiring surgical consultation/interventions. Majority of the times these are cystic masses, but solid giant abdominal masses are also encountered. A thorough clinical examination coupled with imaging and some tumour markers is essential to make a proper diagnosis and to provide adequate and proper treatment.

#### Materials and Methods

A total of thirty cases of giant abdominal masses presented to our unit from April 2016 to December 2021.

#### Results

Ovarian cyst followed by Adnexal cyst/mass were the common diagnosis. Retroperitoneal sarcoma and Mesenteric cyst also presented as giant abdominal masses. CT scan played important role in defining the lesion. MRI was used in selected patients. All pathologies were treated successfully surgically followed by chemoradiation wherever required.

#### Conclusions

In the era of advanced health awareness and widely available diagnostic radiological modalities, patients with giant abdominal mass do present in the surgical clinics with diverse pathologies but the ovary and adnexa still remain the commonest sites followed by mesentery. GIST and retroperitoneal tumours are also encountered as giant abdominal masses and all these can be diagnosed by various available imaging modalities followed by surgical treatment and chemoradiations on case to case basis.

**JK-Practitioner2024;29(1):25-29**

### Introduction

Giant abdominal mass used to be one of the common problems encountered in surgical outpatient and emergency in pre ultrasound era<sup>1,2</sup>. Some of the patients with cystic abdominal masses may require emergency exploratory laparotomy while others can be managed initially by conservative means followed by definitive surgery later<sup>3,4,5</sup>. The presentation of large abdominal masses is rarely seen in clinical practice as early access to medical investigations and imaging is readily accessible<sup>6</sup>. It is not uncommon to have a patient presenting with giant abdominal mass as patient seek medical help during advanced stage of the disease especially in developing countries. A variety of factors may contribute to the late presentation of the patient to the medical setup, such as financial constraints, inaccessible medical facilities in rural areas, fear of finding a terminal diagnosis, and self-diagnoses of patients of getting obese<sup>7,8</sup>.

### Author Affiliations

**Talib Hussain, Sanjay Sharma,**  
Assistant Professors; **Abhinav Mani,**  
Consultant ; **Sanjay Kumar Bhasin,**  
Professor:  
Postgraduate Department of Surgery,  
Government Medical College Jammu,  
Jammu and Kashmir, India.  
Jammu

### Correspondence

Dr. Sanjay Kumar Bhasin  
Postgraduate Department of Surgery,  
Government Medical College Jammu,  
Jammu and Kashmir, India.  
+919419141891  
sanjaykbhasin@yahoo.co.in

### Indexed

EMBASE ,SCOPUS , IndMED ,ESBCO,  
Google Scholar besides other national  
and international databases

### Cite this article as

Talib T , Sharma S, Mani A , Bhasin SK.  
Profile of Giant Abdominal Masses: An  
Experience of 30 Cases and Review of  
Literature. JK Pract2024;29(1):25-29.

Full length article available at  
**Jkpractitioner.com** one month after  
publication

### Keywords

Adnexal mass, Giant abdominal masses,  
GIST, Ovarian cyst, Retroperitoneal mass

### Introduction

There are a wide array of pathologies presenting as huge abdominal masses like mesenteric cysts, benign and malignant ovarian and para-ovarian tumours, GISTs, retroperitoneal tumours etc<sup>9</sup>. Various imaging modalities are used in making a diagnosis and then are treated surgically followed by adjuvant therapy wherever indicated. Regular follow up is advised to look for any recurrence. Herein we are presenting profile of 30 cases of giant abdominal masses presented to our unit in last 05 years.

### Material and methods

The present study conducted in Postgraduate Department of Surgery, Government Medical College Jammu from April 2016 to December 2021 includes thirty patients with giant abdominal mass in the age group of 12 to 75 years. History was taken and all routine baseline investigations were carried out followed by radiologic imaging tests. Ultrasound abdomen and pelvis was done in all patients followed by CECT abdomen and pelvis in majority of patients and MRI abdomen/pelvis in selective patients. After proper optimization and pre-anaesthetic check up, all patients were treated surgically followed by adjuvant chemoradiation wherever required.

### Results

Our study included thirty patients among which 10(33.33%) were males and 20(66.67%) females. 10 patients presented in casualty with abdominal pain/distension and 20 patients reported to surgical OPD. Age/gender distribution and various clinical presentations are shown in table 1 and table 2 respectively.

08 patients presented with huge ovarian cyst with two torsions in the age group of 18 to 75 years, in addition 01 ovarian cyst with large fundal mass and two giant adnexal mass were also seen in the age group of 41 to 70 years. Ovarian cystectomy was done in all the six patients, Salpingo-oophorectomy was performed in two patients owing to torsion involving fallopian tubes (Figure 1). Two females patients age 61 years & 65 patient had large right adnexal solid cystic mass lesion with serum CEA levels of 368.9U/ml and 700.7U/ml and one patient with ovarian cyst and large fundal mass were subjected to total abdominal hysterectomy with bilateral salpingo-oophorectomy with infracolic omentectomy in adnexal mass (Figure 2). Histopathologic evaluation revealed of two patients revealed adenocarcinoma in the mass and leiomyoma with benign endometrial polyp with features of chronic non-specific cervicitis in the fundal mass.

Dr.Zaffar A KhatibThe next common pathology was liver hydatid cyst in 06 patient presenting as huge abdominal mass in 02 male and 04 female patients. Two patients had mesenteric cyst, one had enterogenous type of mesenteric cyst, which was treated by excision of mesenteric cyst with adjacent jejunum and jejunojejunostomy (Figure 3). Other patient had chylolymphatic/simple type of mesenteric cyst which

could be resected without ligating mesenteric vessels and without resecting adjacent small bowel.

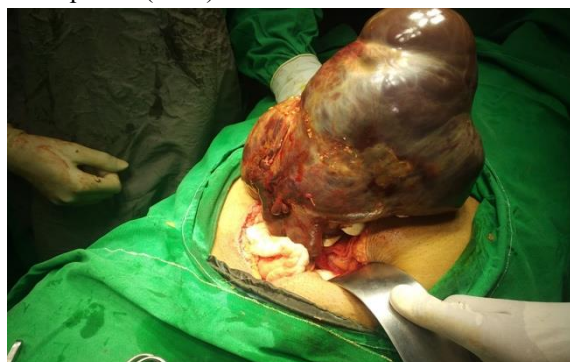**Table 1. Age and Gender distribution**

Age group ( in years)	Male	Female
<20	1	2
21-30	2	5
31-40	2	5
41-50	2	3
51-60	1	3
61-75	2	2
Total	10	20

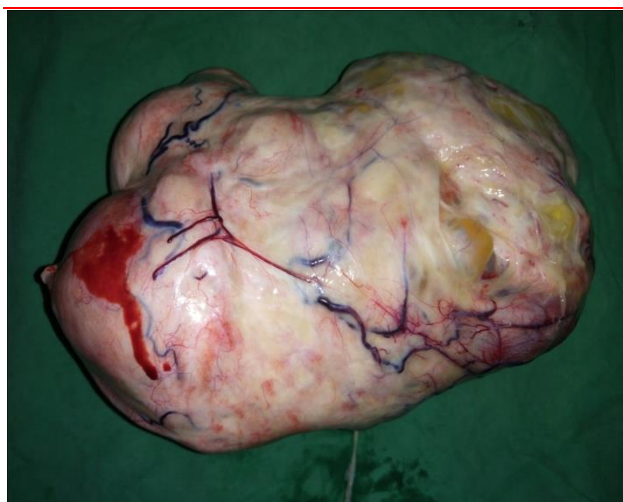
**Table 2. Presentations and diagnosis.**

Presentation	Diagnosis	Number of patients
Pain, lump	Ovarian cyst(8), Hydatid liver(6), Renal mass(2), Hydatid pelvis(2), Splenomegaly with hereditary spherocytosis(1), UDT with Retroperitoneal Mass (1)	20
Lump, discomfort, pain	Retroperitoneal mass	3
Abdominal discomfort, heaviness	Mesenteric cyst(2), Jejunal GIST(2)	3
Menstrual irregularities	Ovarian cyst with uterine fibroid(1), Right adnexal mass(2)	3
Lump, fever, pain	Pyometra	1

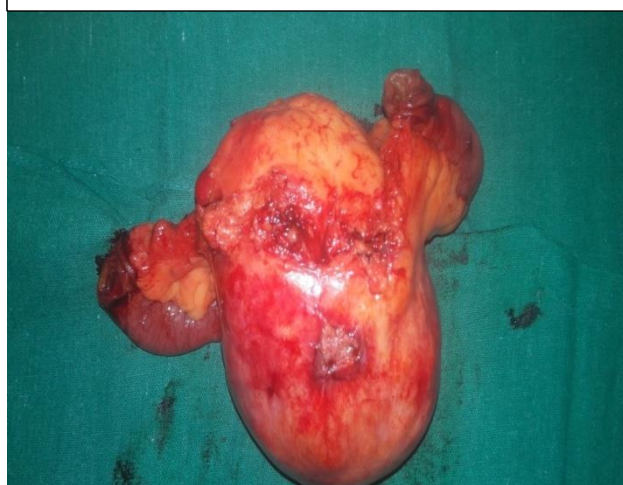
One 12 years old female patient was referred from gynaecology department with large abdomino-pelvic lesion with clitoromegally (Figure 4). CECT abdomen and pelvis was done before intervention. In view of absence of peritonism and fever with exclusion of hydatid disease, percutaneous pigtail catheter drainage was done under local anaesthesia under ultrasonographic guidance. About two litres of pus drained, symptoms improved and distension subsided. Patient is being evaluated for disorders of sexual development (DSD).



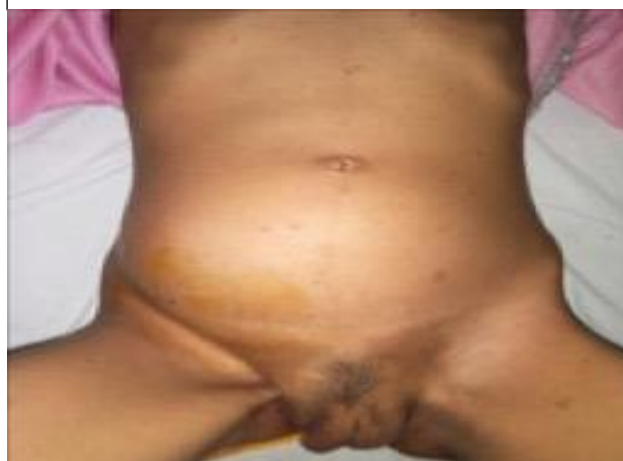**Figure 1. Intra-operative photograph showing large right ovarian cyst, after detorsion.**



**Figure 2. Excised right adnexal mass.**



**Figure 3. Excised jejunal mesenteric cyst with adjacent bowel.**



**Figure 4. Large abdomino-pelvic mass (Pyometra) with clitoromegaly.**

### Discussion

Giant abdominal masses have become rare in the current era of medical practice, due to early detection on routine check-ups and available ultrasonographic facilities even in remote areas. But still a good number of patients present with giant abdominal masses due to

the rapidity of disease progression or the negligence of patients especially in the developing countries.

The masses include gynaecological pathologies, those arising from Gastrointestinal tract, urinary tract, retroperitoneal tumour, desmoids and peritoneal carcinomatosis. The gynaecological pathologies include ovarian and para-ovarian cysts, malignancies, tubo-ovarian abscess, fibroma, endometriosis, hydrosalpinx, hematometra and pyometra<sup>10</sup>.

The masses from GIT include mesenteric cysts, appendicular abscess, malignancies like GIST, Adenocarcinoma, Lymphoma etc<sup>11,12</sup>.

The ovarian cyst can range from a few centimetres to a mass larger than a full-term pregnancy. Various imaging modalities are used for diagnosing ovarian tumours. Ultrasonography is initial imaging modality followed by CT or MRI if required especially to obtain further information (septations, solid component, mural nodules, internal growth etc) and the metastatic involvement. Serial measurements of CA-125 is of great help<sup>13</sup>.

Almost all large tumours are managed surgically even if benign, which includes ovarian cystectomy<sup>14</sup>. Total abdominal hysterectomy along with bilateral salpingo-oophorectomy with partial (infracolic) omentectomy with lymph node sampling is done in cases of postmenopausal women, as every postmenopausal woman with an ovarian cyst or mass should be suspected for ovarian malignancy due to higher incidence of ovarian cancer in this age group. Mesenteric cysts are rare, benign intra-abdominal cystic lesions of the gastrointestinal mesentery, with an incidence of 1/100000 in adults and 1/20000 in children, and a female to male ratio of 2:1, which commonly present in the second decade of life<sup>15</sup>. We encountered two mesenteric cysts, both females and in their fourth decade of life.

Mesenteric cysts can occur in any part of the mesentery from the duodenum to the rectum<sup>16</sup>. They occur more often in the small intestine (66%) than the large intestine (33%)<sup>17</sup>. Mesenteric cysts are of four types: developmental, traumatic, infective and neoplastic<sup>18</sup>. Developmental cysts include enterogenous, urogenital remnant, dermoid and chylo-lymphatic cysts<sup>19</sup>.

Mesenteric cysts may present with acute or chronic abdominal pain (55%-81%), palpable mass (44%-61%), distension (17%-61%), nausea and vomiting (45%), constipation (27%) and diarrhoea (6%). In severe cases, it can lead to bowel obstruction, obstructive uropathy, volvulus and peritonitis, usually from a haemorrhagic or infective cyst<sup>20</sup>.

A variety of diagnostic modalities can be used to confirm the presence of a mesenteric cyst, but USG and CT scan tend to be the favoured methods<sup>21</sup>.

Surgical excision of the mesenteric cyst, with or without resection of adjacent bowel is the common management approach, with marsupialisation reserved for cases that may require wide resection of adjacent

organs, but the recurrence rate is high. Drainage is no longer advised due to infection and recurrence risks<sup>22</sup>. Gastrointestinal stromal tumours (GISTs) as such are rare malignancy but are the most common mesenchymal tumour of the gastrointestinal (GI) tract. These tumours were historically categorized as leiomyomas or leiomyosarcomas, and thus remained largely unrecognized as a separate classification until the 1980s. CD117 (tyrosine kinase receptor known as KIT) immunohistochemistry staining is now widely accepted as a criterion for a pathologic diagnosis of GIST<sup>23</sup>. In KIT-negative tumours, the diagnosis continues to rely on histologic features. GISTs contain a variable combination of spindle cells and epithelioid cells. GIST arise from the interstitial cells of Cajal (ICC). The ICC were identified in 1893 by Santiago Ramon y Cajal. GISTs may be found throughout the gastrointestinal tract, from the oesophagus to the internal anal sphincter. The most common gastrointestinal location is the stomach (50% to 60%), followed by the small intestine (20% to 25%), rectum (5%), and oesophagus (2%). Other less common locations where GIST has been identified include the omentum and genitourinary tract<sup>24</sup>.

The symptoms of GIST are related to the size and location of the tumour. Patients presenting with large GISTs may have palpable tumours and present with symptoms of pressure or pain. Patients with smaller tumours may present with acute gastrointestinal blood loss or symptoms of chronic anaemia and associated fatigue. CT findings include a submucosal mass with smooth borders or a rounded appearance, or an exophytic lobulated lesion.

The mainstay of therapy remains surgical resection. A subtotal gastrectomy or even gastric wedge resection is most often adequate to achieve grossly negative margins.

Lymph node dissection does not aid in staging or treatment and should only be undertaken in the rare patients with grossly positive nodal metastases. Large tumours, greater than 10 cm, should be considered for neoadjuvant therapy to maximize organ preservation. Imatinib (biologic agent, tyrosine kinase receptor inhibitor) is used for recurrent, locally invasive, or metastatic GIST. Sunitinib is used in patients who are either refractory to imatinib or who are unable to tolerate imatinib.

Radiotherapy is ineffective and is currently reserved for rare cases of isolated local recurrence in low rectal lesions.

### Conclusions

Majority of the giant abdominal masses comprise of tubo-ovarian masses. Presentation can be diverse. Various imaging modalities can be used for a proper diagnosis and can be successfully treated surgically. Hysterectomy with bilateral salpingo-oophorectomy with infracolic omentectomy with lymph node sampling should be considered in adnexal masses in cases of postmenopausal women.

### Conflict of Interest

The authors declared that there is no conflict of interest.

### Acknowledgements

The research received no funding from any source.

### References

- 1 Symmonds RE, Spraitz AF Jr, Koelsche GA. Large ovarian tumour. Report of a case. *Obstet Gynecol* 1963; 22:473-7.
- 2 Bennington JL, Ferguson BR, Haber SL. Incidence and relative frequency of benign and malignant ovarian neoplasms. *Obstet Gynecol* 1968; 32:627-32.
- 3 Hoile RW. Hazards in the management of large intra-abdominal tumours. *Ann R Coll Surg Engl* 1976; 58:393-7.
- 4 Sujatha VV, Babu SC. Giant ovarian serous cystadenoma in a postmenopausal woman: a case report. *Cases J*. 2009; 2:7875.
- 5 Akhras LN, Akhras LN, Farooq S, AlSebay L: A 27-kg giant ovarian mucinous cystadenoma in a 72-year-old postmenopausal patient: a case report. *Am J Case Rep*. 2019, 20:1601-6.
- 6 Kim YT, Kim JW, Choe BH: A case of huge ovarian cyst of 21-year-old young woman *J Obstet Gynaecol Res*. 1999, 25:275-9.
- 7 Agrawal SP, Rath SK, Aher GS, Gavali UG. Large ovarian tumor: a case report. *Int J Sci Study*. 2015, 3:143-5.
- 8 Madhu YC, Harish K, Gotam P: Complete resection of a giant ovarian tumour. *Gynecol Oncol Case Rep*. 2013, 6:4-6.
- 9 Mathur P, Dave A, Gaur P et al. Clinicopathologic study of large abdominal masses in gynaecological practice and their outcome. *Int J Reprod Contracept Obstet Gynecol*. 2016 Feb; 5(2):503-508.
- 10 ACOG Practice Bulletin. Management of adnexal masses. *Obstet Gynecol*. 2007; 110(1):201-14.
- 11 Barker CS, Lindsell DRM: Ultrasound of the palpable abdominal mass. *Clin Radiol* 41:98, 1990.
- 12 Haider A, Mehershahia S, Siddiqua A, Sharma M, Patel H. Imatinib-Resistant Gastrointestinal Stromal Tumour Presenting as a Large Abdominal Mass. *Case Rep Gastroenterol* 2021; 15:736-741.
- 13 Kotis A, Karatapanis S, Papamargaritis V, Lisgos P, Sisamotos G. A case of a large ovarian tumour. *BMJ Case Rep* 2011; 2011.
- 14 A. Alobaid, A. Memon, S. Alobaid, and L. Aldakhil, "Laparoscopic Management of Huge Ovarian Cysts," *Obstetrics and Gynecology International*, vol. 2013, pp. 1-4, 2013.
- 15 Liew SC, Glenn DC, Storey DW. Mesenteric cyst. *Aust N Z J Surg* 1994; 64:741-744.
- 16 Wang JH, Lin JT, Hsu CW (2012) Laparoscopic excision of mesenteric duplication enteric cyst embedded in sigmoid mesocolon mimicking retroperitoneal neurogenic tumor in adults. *Surg Laparosc Endosc Percutan Tech* 22: e294-6.
- 17 Emedicine Medscape (2013) Mesenteric and omental cysts.
- 18 Beahrs OM, Judd ES Jr, Dockerty MB. Chylous cysts of the abdomen. *Surg Clin North Am* 1950; 30:1081-96.
- 19 Mann CV. The peritoneum, omentum, mesentery and retroperitoneal space. 22 nd ed. *Bailey and Love's short practice of surgery* In: Mann CV, Russell RC, Williams NS, editors. London: Chapman and Hall; 1995. p. 764-80.

- |    |   |    |  |
|----|---|----|--|
| 20 | Prakash A, Agrawal A, Gupta RK, Sanghvi B, Parelkar S. Early management of mesenteric cyst prevents catastrophes: a single centre analysis of 17 cases. <i>Afr J PaediatrSurg</i> 2010; 7: 140-143. | 22 | Vu JH, Thomas EL, Spencer DD. Laparoscopic management of mesenteric cyst. <i>Am Surg</i> 1999; 65: 264-265.            |
| 21 | Mason JE, Soper NJ, Brunt LM. Laparoscopic excision of mesenteric cysts: A report of two cases. <i>Surg Laparosc Endosc Percutan Tech</i> 2001; 11:382-4.   | 23 | Corless CL, Fletcher JA, Heinrich MC: Biology of gastrointestinal stromal tumours. <i>J Clin Oncol.</i> 22: 3813 2004. |
|    |   | 24 | Judson I: Gastrointestinal stromal tumours (GIST): Biology and treatment. <i>Ann Oncol.</i> 13:287 2002.               |